

# **Circumcision and Meatal Stenosis of Boys with Bladder/Urethral Stones in a Hospital in Northern Ghana: Case Series**

**Akisibadek Alekz Afoko<sup>1,2</sup>, Yussif Adams<sup>3\*</sup> and Vivian Afoko<sup>4</sup>**

<sup>1</sup>Department of Surgery, School of Medicine, University for Development Studies, Ghana.

<sup>2</sup>Urology Unit, Tamale Teaching Hospital, Tamale, Ghana.

<sup>3</sup>Department of Biomedical Laboratory Science, School of Allied Health Sciences, University for Development Studies, Tamale, Ghana.

<sup>4</sup>Department of Paediatric Nursing, School of Nursing and Midwifery, University for Development Studies, Ghana.

## **Authors' contributions**

*This work was carried out in collaboration among all authors. Authors AAA and YA designed the study, performed the statistical analysis, wrote the protocol and wrote the first draft of the manuscript. Authors YA and VA managed the analysis of the study, software and did the validation. Author AAA managed the literature searches. All authors read and approved the final manuscript.*

## **Article Information**

### Editor(s):

(1) Dr. Ahmet Tahra, Istanbul Medeniyet University, Turkey.

(2) Dr. Muhammad Ujudud Musa, Federal Medical Centre, Nigeria.

(3) Dr. Punit Bansal, RG Stone and Superspeciality Hospital, India.

### Reviewers:

(1) Behzad Narouie, Zahedan University of Medical Sciences, Iran.

(2) Marcelo Lopes de Lima, Campinas State University, Brazil.

Complete Peer review History: <https://www.sdiarticle4.com/review-history/72706>

## **Case Report**

**Received 11 August 2021**

**Accepted 21 October 2021**

**Published 28 October 2021**

## **ABSTRACT**

Neonatal circumcision of boys is a common practice among people living in Northern Ghana. These case series included 22 boys between the ages of 17–60 months admitted to the pediatric emergency ward of a tertiary hospital. All the boys diagnosed with meatal stenosis (20/22) were circumcised within 14 weeks after birth, 1 of 22 had hypospadias with preputial hood with a pin-point meatus, and the other was not circumcised. Among the 22 cases, all presented with recurrent urinary tract infections (UTIs) with *proteus* (68.2%), *Klebsiella* species (22.7%), *pseudomonas*, and *Serratia marcescens* (4.5% respectively) isolated from urine cultures. Routine abdomino-pelvic ultrasound scans (kidney, ureter, bladder [KUB]) as well as ultrasound of the urethra and perineum

\*Corresponding author: Email: [adamsyussif@uds.edu.gh](mailto:adamsyussif@uds.edu.gh);

were performed of which 13 of 22 children had stones in the bladder, 6 of 22 stones found in fossa navicularis, and 3 in the bulbar urethra. Meatal stenosis was a common finding among neonates after early circumcision and this needs to be made known as part of informed consent before neonatal circumcision. Surgically, a well-performed meatoplasty was carried out to correct it. In children whose stones were present in the bladder, these were fragmented and removed. More distal stones in the fossa navicularis were extracted after meatotomy. A delay in circumcision to later in life (at least 6 months after birth) is recommended as well as intensified educational programs on meatal stenosis, urinary tract infections, and blood borne infections in the communities since widespread neonatal circumcision is often carried out by “quacks doctors” (untrained native doctors). A balanced diet and adequate water intake will help prevent bladder or kidney stones formation.

**Keywords:** Neonatal circumcision; meatal stenosis; pediatrics; hypospadias; meatoplasty.

## ABBREVIATIONS

CFU – Colony-forming unit  
 CI – Confidence interval  
 KUB – Kidney, ureter, bladder  
 LUTS – Lower urinary tracts symptoms  
 TIP – Tabularised Incised Plate  
 TTH – Tamale Teaching Hospital  
 UTIs – Urinary tract infections

## 1. INTRODUCTION

Meatal stenosis is an atypical narrowing of the opening (meatus) of the urethra. This complication is a common urologic complaint after circumcision [1-3] with a prevalence in 9-10% of males [1]. Many circumcised boys experience problems such as dysuria, difficult-to-aim urinary stream, upward deflection of urine, abdominal discomfort, and painful urination, and if left unmanaged, can cause kidney problems or lead to urinary tract infections (UTIs) [1].

Subsequently, many practitioners may downplay the risk of meatal stenosis following neonatal circumcision. This study, therefore, provides a cases report of symptomatic meatal stenosis among boys admitted to the pediatric urology unit of the Tamale Teaching Hospital, Northern region of Ghana.

## 2. PRESENTATION OF CASES

A total of 22 boys between the ages of 17–60 months admitted to the pediatric urology unit of the Tamale Teaching Hospital from February 2019 to August 2020 were presenting similar symptoms; voiding complaints, dysuria, abdominal discomfort, and stream abnormalities.

On physical examination, the majority (72.7%) had deflected/spray urine, 13.6% presented with

rectal prolapse, and all (100%) had severe lower urinary tracts symptoms (LUTS). Circumcision status was determined and a majority (90.9%) had been circumcised within 14 days after birth. One boy was not circumcised and the other had hypospadias with preputial hood with pin-hole meatus. About 91% (20/22) presented with round narrow meatus, one person with pin-point narrow meatal opening of approximately 1 millimeter (Fig 1 A and B), and the other uncircumcised boy did not show stenosis of the meatus.

Urinalysis and urine culture results showed; all the boys (22/22) had recurrent urinary tract infections (UTIs) with 36.4% (8/22) presenting with haematuria. All urine samples were positive for urine cultures and the organisms isolated were *Proteus* (68.2%), *Klebsiella* species (22.7%) with *Pseudomonas* and *Serratia marcescens* being the least (4.5% respectively) (Table 1). The organisms isolated were susceptible to the following antibiotics: Amikacin 22 samples (100% susceptibility), Gentamicin 22 samples (100% susceptibility), Meropenem 22 samples (100% susceptibility), Ciprofloxacin 4 samples (18.2% susceptibility), Amoxicillin Clavulanic Acid 7 samples (31.8% susceptibility) and cefuroxime 7 samples (31.8% susceptibility). However, there was resistance to Cotrimoxazole for all samples (0% susceptibility).

A Routine abdomino-pelvic ultra-sound scan (kidney, ureter, bladder [KUB]) as well as ultrasound of the urethra and perineum were performed on all patients. Most (59.1%) of the boys had stones in their bladder, 27.3% of stones were located in fossa navicularis (Fig. 3) while 13.6% of the stones could be found in the bulbar urethra. A majority (54.5%) of these stones were composed of struvite and 9.1% were ammonium urate crystals (Table 1).

As shown in Fig 2, the diameter (millimeters) of each stone was measured. For stones in the bladder, the median (minimum-maximum) was 19 (8–35) mm. Stones in fossa navicularis had a diameter of 3.5 (3–5) mm while stones in the bulbar urethra had the same diameter of 4 mm.

### 3. DISCUSSION

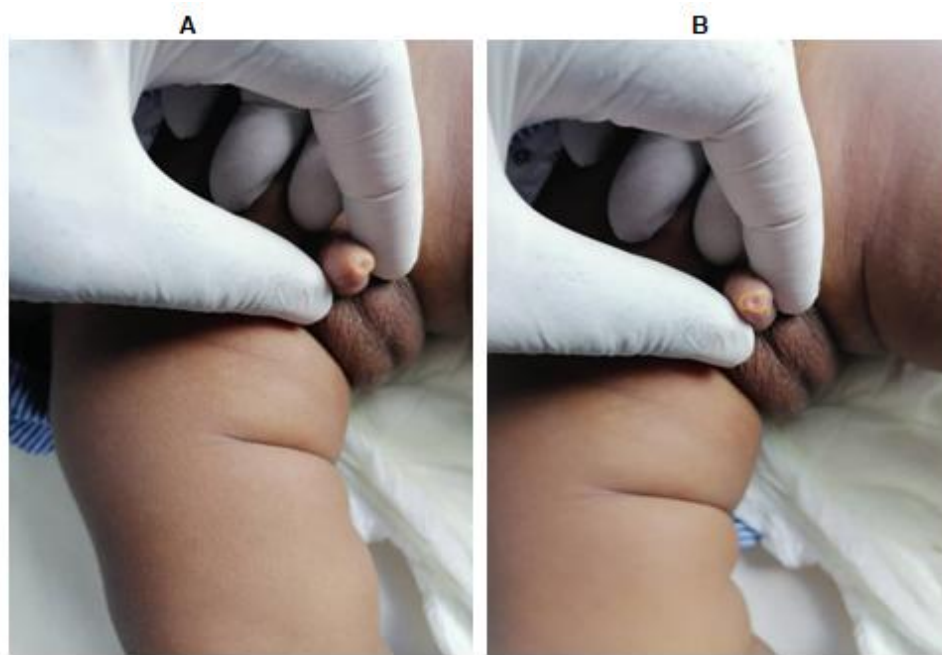
Neonatal circumcision of boys is a common practice among the Ghanaian populace especially among people living in the northern sector. This activity is often carried out few days after a male child is born. Many boys experience

problems well after the initial scars have healed. Studies have shown that urethral meatal stenosis is a common complication of male circumcision [1-4] especially within few days of birth. Van Howe [2] reported that, of the 1,100 subjects who received 2,068 genital examinations, the incidence of meatal stenosis in circumcised boys was 2.78% (95% CI: 1.76-3.79) while none of the uncircumcised boys was diagnosed with meatal stenosis. In these case series, majority of the patients were circumcised within 14 days after birth and this may have accounted for the high incidence of meatal stenosis as reported.

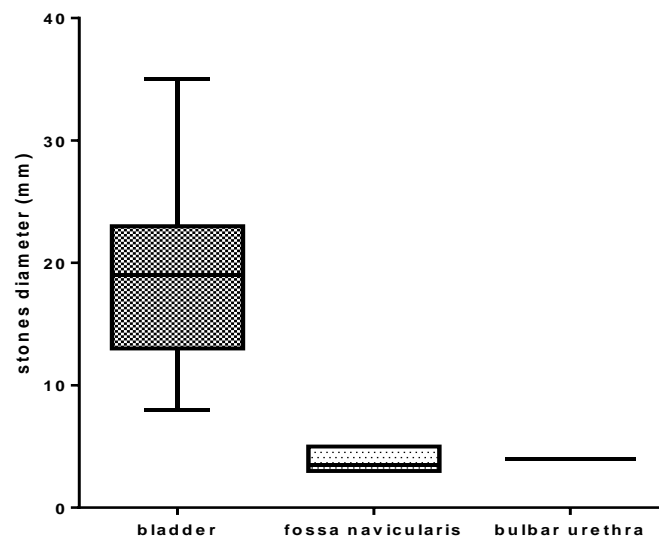
**Table 1. Clinical characteristics of study participants**

Variables	Frequency (n=22)	Percent (%)
Age (Months)		
<30	7	31.8
30-60	15	68.2
Non-specific Abdominal Pain		
Present	7	31.8
Deflection/spraying of urine		
Present	16	72.7
Rectal prolapse		
Present	3	13.6
Severe LUTS		
Present	22	100
Circumcision within 14 days after birth		
Yes	20	90.9
Hypospadias with preputial hood	1	4.5
Uncircumcised (stenotic prepuce)	1	4.5
Round narrow meatus		
Present	20	90.9
Present (pin hole)	1	4.5
Absent	1	4.5
Recurrent UTIs		
Present	22	100
Haematuria		
Present	8	36.4
Absent	16	72.7
UTI with positive culture		
Present	22	100
Urine culture isolates		
<i>Proteus</i>	15	68.2
<i>Pseudomonas</i>	1	4.5
<i>Klebsiella spp</i>	5	22.7
<i>Serratia marcescens</i>	1	4.5
Site of stone		
Bladder	13	59.1
Fossa navicularis	6	27.3
Bulbar urethra	3	13.6
Stone composition		
Ammonium Urate	2	9.1
Carbapatite	8	36.4
Struvite	12	54.5

Data presented as number (percent)



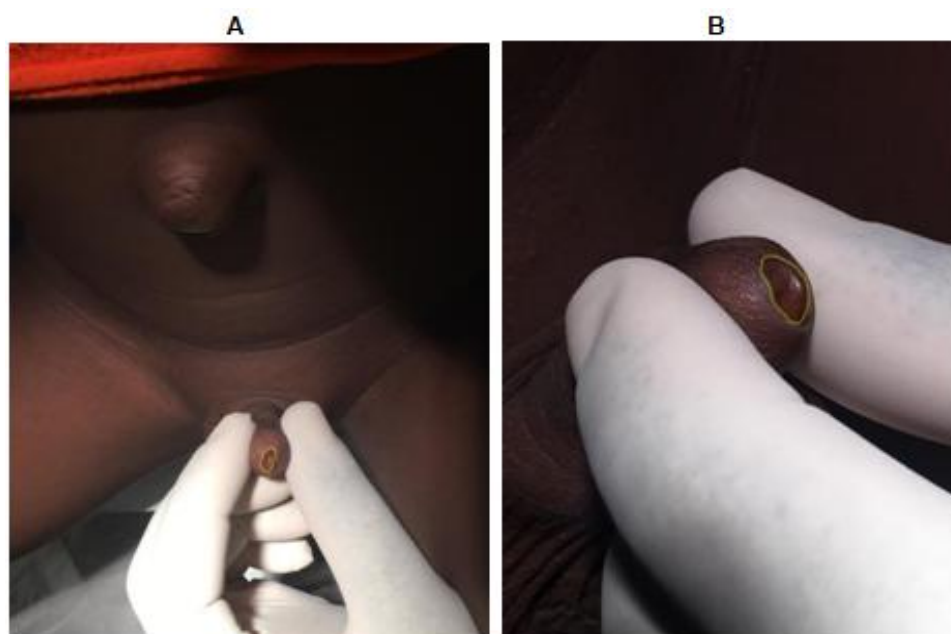
**Fig. 1. A picture showing pin-point narrow meatal opening (circled in yellow) of approximately 1 millimeter (A and B)**



**Fig. 2. Location and diameter of bladder/urethra stones**

The majority of the boys presented with round narrow meatus with one boy showing a pin-hole meatal opening of approximately 1 millimeter or smaller. These findings were consistent with Allen and Summers [5] who reported significant meatal stenosis in 578 children of whom at least a third had a “pin-point meatus”.

Classical symptoms of meatal stenosis include; penile pains at micturition initiation, deflected/spray urine, narrow high-velocity stream, severe lower urinary tracts symptoms which may result in the need to stand or sit back on the toilet bowl to urinate [6]. The frequency of these symptoms was reported in these case series.



**Fig. 3. This picture shows one of the findings in which a palpable stone (circled in yellow) was found in the fosa navicularis. Meatotomy was done to extract the stone followed by meatoplasty**

Meatal stenosis can lead to serious UTIs and predispose to vesicoureteric reflux, decompensation of the bladder, hydronephrosis, and kidney failure [7, 8]. Children with meatal stenosis are more likely to have difficulty in urination. Inability to void urine promotes urinary tract infections (UTIs) due to urine retention. This may lead to infectious bladder resulting in stone formation and subsequently to recurrent UTI with severe LUTS. All the boys in these cases had severe lower urinary tracts symptoms and recurrent UTIs with *Proteus*, *Klebsiella*, *Pseudomonas*, and *Serratia marcescens* being the organisms isolated in the urine cultures.

Urinary stasis promotes urinary crystals and subsequent stone formation. Studies have reported that a urinary environment in which stones form, urine retention is very common [9,10]. Gault *et al.*, [11] found 7 of 132 renal stones, 5 out of 105 ureteral, and 6 of 21 bladder stones surgically using infrared and wet chemical analysis. The stone analysis showed that magnesium ammonium phosphate was present but calcium phosphate crystals predominated [11]. In these cases, however, we found 3 of 22 bulbar urethral, 6 of 22 fosa navicularis, and 13 of 22 bladder stones employing an abdominal, perineal, and penile ultra-sound scan. The stone analysis revealed struvite (magnesium ammonium phosphate) as the most common

among patients, with the least being carbapatite and ammonium urate crystals. These stones are commonly caused by infection and their presence perpetuates the UTI thereby leading to a vicious cycle. It appears that the presence of stones led to severe lower urinary tract symptoms (LUTS). The risk of UTI is significant and may lead to the formation of infectious stones in the urinary tract as seen in these cases. Increase intake of fluid works in all types of stones, hence, a balanced diet with plenty of water intake is recommended for the prevention of recurrence of stones [12,13].

Initial urine cultures yielded higher than  $10^5$  CFU/ml in all cases. Urine culture and sensitivity results guided the initial antibiotic therapy of the UTI to render the urine 'sterile' before definitive treatment. In 16 (72.7%) out of 22 cases, this was achieved. In 6 out of 22 (27.3%) cases there was a significant reduction ( $10^3$  CFU/ml). Definitive treatment consisted of meatotomy followed by lithotripsy with EMS Lithoclast2 and extraction of stone fragments. Meatoplasty was then carried out. Distal stones in the fosa navicularis were readily extracted following meatotomy and did not require prior fragmentation. Patients received Gentamicin 2.5mg/Kg in divided doses starting more than 24 hours before operation followed by 24 hours postoperatively. Urinary catheters were removed

24 hours after surgery and patients were discharged.

All surgeries were done under general anesthesia. Meatoplasty was carried out for all the patients with round meatal stenosis, with pre-operative suppository paracetamol administered to serve as post-operative analgesia. In the case of hypospadias with preputial hood, hypospadias repair was carried out using the Tabularised Incised Plate (TIP) technique as described by Nguyen *et al.*, [14]. For the case of the stenotic prepuce, circumcision was carried out under local infiltration with 1% plain lidocaine using an insulin syringe and needle.

#### 4. CONCLUSION

Meatal stenosis is a common complication that occurs almost exclusively in circumcised males. A detailed clinical history and physical examination will help in the diagnosis of this problem especially in circumcised boys with abdominal or urinary complaints. Disclosure of the risk of meatal stenosis when informed consent is obtained for circumcision in various health facilities, and delay of circumcision to later in life (at least 6 months after birth) is recommended. Also, educational programs on meatal stenosis, urinary tract infections as well as blood-born infections should be intensified in the communities since neonatal circumcision is often carried out by “quacks doctors” (untrained native doctors).

#### CONSENT

All authors declare that written informed consent was obtained from the mothers and caregivers for publication of this Case series and accompanying images.

#### ETHICAL APPROVAL

All authors hereby declare that all experiments have been examined and approved by the Ethics and Review Board of the Department of Research and Development, Tamale Teaching Hospital, and have therefore been performed following the standards laid down in the 1964 Declaration of Helsinki.

#### ACKNOWLEDGEMENTS

We acknowledged the senior staff and the nurses of the paediatric ward of the tamale

teaching hospital not forgetting the nurse-in-charged. We also thank the mothers/caregivers of these children for their support in this study.

#### COMPETING INTERESTS

Authors have declared that no competing interests exist.

#### REFERENCES

1. Wang MH. Surgical management of meatal stenosis with meatoplasty. *Journal of Visualized Experiments: JoVE*. 2010; 45.
2. Van Howe RS. Incidence of meatal stenosis following neonatal circumcision in a primary care setting. *Clinical Pediatrics*. 2006;45(1):49-54.
3. Kunz H. Circumcision, and meatotomy. *Primary care*. 1986;13(3):513.
4. King L. Neonatal circumcision in the United States in 1982. *J Urol*. 1982;128:1135-1136.
5. Allen J, Summers J. Meatal stenosis in children. *J Urol*. 1974;112:526-527.
6. Persad R, Sharma S, McTavish J, Imber C, Mouriquand P. Clinical presentation and pathophysiology of meatal stenosis following circumcision. *British Journal of Urology*. 1995;75(1):91-3.
7. Eke FU, Eke NN. Renal disorders in children: a Nigerian study. *Pediatric Nephrology*. 1994;8(3):383-386.
8. Brem J, Jaffee S. Hidden meatal stenosis in male infants and children. *American family physician/GP*. 1970;2(2):72-73.
9. Childs MA, Mynderse LA, Rangel LJ, Wilson TM, Lingeman JE, Krambeck AE. Pathogenesis of bladder calculi in the presence of urinary stasis. *The Journal of Urology*. 2013;189(4):1347-1351.
10. Stav K, Dwyer PL. Urinary bladder stones in women. *Obstetrical & Gynecological Survey*. 2012;67(11):715-725.
11. Gault M, Longerich L, Crane G, Cooper R, Dow D, Best L, *et al.* Bacteriology of Urinary Tract Stones. *The Journal of Urology*. 1995;153(4):1164-1170.
12. Finkelstein VA, Goldfarb DS. Strategies for preventing calcium oxalate stones. *Cmaj*. 2006;174(10):1407-1409.
13. Akhtar J, Ahmed S, Zamir N. *Management of impacted ureteral stones in children*. *J Coll Physicians Surg Pak*. 2012;22(8): 510-3.

14. Nguyen MT, Snodgrass WT. Effect of urethral plate characteristics on tubularized incised plate urethroplasty. The Journal of Urology. 2004;171(3):1260-1262.

---

© 2021 Afoko et al.; This is an Open Access article distributed under the terms of the Creative Commons Attribution License (<http://creativecommons.org/licenses/by/4.0>), which permits unrestricted use, distribution, and reproduction in any medium, provided the original work is properly cited.

*Peer-review history:*  
*The peer review history for this paper can be accessed here:*  
<https://www.sdiarticle4.com/review-history/72706>